



Royal Diagnostic

Mob. 9829944500 | E-mail : royaldiagnostic500@gmail.com

Fully Computerised & Air-Conditioned Laboratory with Modern Technology

Shop No. 12, Ground Floor, Vinayak City Plex, Bajrang Kanta, Sikar-332001 (Raj.)

HEALTH CHECK UP

Enroll No. F-F Marka Examination Date 29/10/2023 Exp. Date 29/11/2023
 Name MOHAMMED ASFAQ KHOKHAR
 Father's Name SHER MOHAMMED KHOKHAR Age 42 Years and 11 Months Sex MALE

Nationality INDIAN Status MARRIED
 Height 173 Weight 74
 Passport No. V-9727562 Place JAIPUR Date 22/06/2022

Passport Applied For ALUMINIUM FABRICATOR

History of any Significant illness including

1. Psychiatric and Neurological Disorders (Epilepsy, Depression) NIL
2. Allergies : NIL
3. Others : NIL

FIT



MEDICAL EXAMINATIONS			LABORATORY EXAMINATIONS		
TYPE OF INVESTIGATION		RESULT	TYPE OF INVESTIGATION		RESULT
EYE	RIGHT	6/6	URINE	SUGAR	NIL
	LEFT	6/6		ALBUMIN	NIL
EAR	RIGHT	NAD	MICROSCOPIC		NAD
	LEFT	NAD		STOOL ROUTINE	NAD
GASTROINTESTINAL EXAM		NAD	OVA CYST & V CHOLERA		NIL
SYSTEMATIC EXAM			BLOOD	HAEMOGLOBIN	15.2 gm%
(A) CARDIOVASCULAR		NAD	MALARIA		NOT DETECTED
(B) BLOOD PRESSURE		126/85	MICROFILARIA		NOT DETECTED
REPIRATORY SYSTEM		NAD	BIOCHEMISTRY		NORMAL
HEART		NAD	BLOOD SUGAR		98 mg/dl
LUNGS		NAD	ABO Rh		WNL
CHEST X-RAY		NAD	CREATININE		0.73 mg/dl
OTHER HERNIA		ABSENT	V D R L		NON REACTIVE
VARIC OSE VEIN		ABSENT	T.P.H.A. (IF V.D.R.L. +VE)		NOT DONE
EXTREMITIES		NAD	HIV 1st & 2nd		NEGATIVE
DEFORMITIES & SKIN		NAD	Hbs Ag/H.C.V.		NEGATIVE

REMARKS : In my opinion..... MOHAMMED ASFAQ KHOKHAR

SHER MOHAMMED KHOKHAR

is.....

DR. R.L. TAYAGI
 M.D. (Medicine)
 CONSULTANT PHYSICIAN
 RMC REG. NO. :32862





Royal Diagnostic

Mob. 9829944500 | E-mail : royaldiagnostic500@gmail.com

Fully Computerised & Air-Conditioned Laboratory with Modern Technology

Shop No. 12, Ground Floor, Vinayak City Plex, Bajrang Kanta, Sikar-332001 (Raj.)

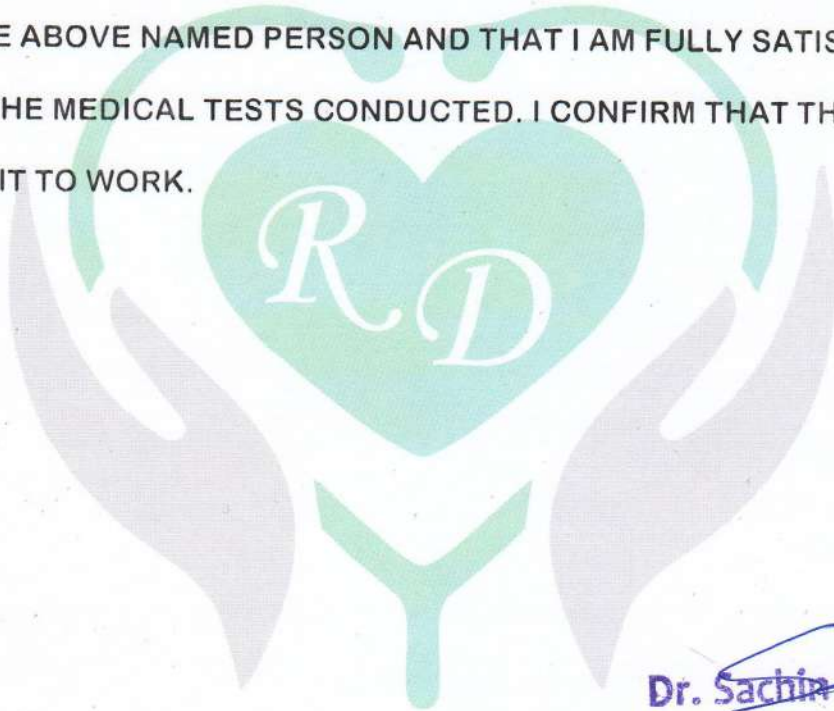
HEALTH CHECK UP

Patient's Name	Mr. MOHAMMED ASFAQ KHOKHAR	Lab No.	SCA/2021/23/132949
Passport No.	V-9727562	DOB	29/11/1980
Date	29/10/2023	SEX	MALE

TO WHOM IT MAY CONCERNED

FITNESS CERTIFICATE

THIS IS TO CONFIRM THAT I DR. SACHIN AGARWAL (M.B.B.S. MD PATHOLOGIST) HAS EXAMINED THE ABOVE NAMED PERSON AND THAT I AM FULLY SATISFIED WITH THE RESULTS OF THE MEDICAL TESTS CONDUCTED. I CONFIRM THAT THIS PERSON IS PHYSICALLY FIT TO WORK.



Dr. Sachin Agarwal
MBBS, M.D. (Path)
DMC NO.: 9245
PATHOLOGIST



HEALTH CHECK UP

Patient's Name	Mr. MOHAMMED ASFAQ KHOKHAR	Lab No.	SCA/2021/23/132949
Passport No.	V-9727562	DOB	29/11/1980
Date	29/10/2023	SEX	MALE

X-Ray Chest PA View.

Lunges Fields Show No Active parenchymal Lesion.

Both c.p. angle are Clear.

Both domes of diaphragm are normal.


Both hilar shadow are normal.

Cardiac shadow is within normal limits.

Impression.. Normal Study

Please correlate clinically and with other relevant investigation to rule out any other Pathology.

Dr. R.L. PAREEK
MD, Radiodiagnosis
Consultant Radiologist



Royal Diagnostic

Mob. 9829944500 | E-mail : royaldiagnostic500@gmail.com

Fully Computerised & Air-Conditioned Laboratory with Modern Technology


Shop No. 12, Ground Floor, Vinayak City Plex, Bajrang Kanta, Sikar-332001 (Raj.)

HEALTH CHECK UP

Patient's Name	Mr. MOHAMMED ASFAQ KHOKHAR	Lab No.	SCA/2021/23/132949
Passport No.	V-9727562	DOB	29/11/1980
Date	29/10/2023	SEX	MALE

SEROLOGY

Test Name	Value	Unit	Reference Value
VDRL	NON - REACTIVE		NON - REACTIVE



Dr. Sachin Agarwal
MBBS, M.D. (Path)
PATHOLOGIST
DMC NO.: 9245



HEALTH CHECK UP

Patient's Name	Mr. MOHAMMED ASFAQ KHOKHAR	Lab No.	SCA/2021/23/132949
Passport No.	V-9727562	DOB	29/11/1980
Date	29/10/2023	SEX	MALE

SEROLOGY

RAPID PLASMA REAGIN (RPR -TITRE TEST)-SYPHILIS

Description	Results	Units	Bio. Ref. Interval
Rapid Plasma Reagin (Rpr -Titre Test)-Vdrl <small>(Methodology Agglutination)</small>	NEGATIVE(1:8)	Titre	1:8 and above are significant

Interpretation Notes :-

Syphilis detection tests are serologic tests used to screen for and confirm infection with T pallidum. These tests have largely replaced direct visualization of spirochetes owing to greater ease of testing, less reliance on observer experience, and less-expensive equipment. The tests are categorized into two serologies: nontreponemal tests and the-treponemal tests. Some common conditions associated with false-positive test results are listed below:-Potential causes of cross-reactivity

Infectious causes

- Malaria
- Tuberculosis
- Viral fevers
- Trypanosomiasis
- Leprosy

Non-infectious causes

- Drug addiction
- Connective tissue disease
- Pregnancy
- Advanced age

REMARK-All positive RPR and VDRL test results should prompt follow-up with FTA-ABS or TP-PA. Biologic false-positive results are defined as a positive RPR/VDRL result with a negative FTA-ABS/TP-PA result and are due to reactivity of autoantibodies to the cardiolipin- lecithin-cholesterol reagent present in the nontreponemal tests.

RESPONSE TO TREATMENT

Nontreponemal (RPR/VDRL) titers can be used to monitor treatment response. Successful treatment is associated with a 4-fold or two-tube decline in titer (ie, from 1:32 to 1:8) 6 months after therapy for primary or secondary syphilis and 1 year after therapy for latent syphilis. RPR and VDRL titers are not interchangeable or convertible, so it is important to use consistent testing with a single method to monitor disease activity. The treponemal (FTA-ABS/TP-PA) tests remain positive for the life of the patient regardless of therapy, and titers are not reported.

Note: The result obtained relate only to the sample given/ received & tested. A single test result is not always indicative of a disease, it has to be correlated with clinical data for interpretation

*** End of Report ***

Dr. Sachin Agarwal
MBBS, M.D. (Path)
PATHOLOGIST
DMC NO.: 9245